

# Prolotherapy For Low Back Pain

A reasonable and conservative approach to musculoskeletal low back pain, disc disease, and sciatica

By Donna Alderman, DO



In the January/February 2007 issue of this journal,<sup>1</sup> a review article on Prolotherapy outlined the use of Prolotherapy for musculoskeletal pain. This is the first of a series of articles which will go into more detail regarding the use of prolotherapy for different areas. This article will discuss the use of prolotherapy for low back pain, disc disease, and sciatica, together with case reports.

### Review

Prolotherapy is a method of injection treatment designed to stimulate healing.<sup>2</sup> Many different types of musculoskeletal injuries and pain lend themselves to prolotherapy treatment including low back and neck pain, chronic sprains and/or strains, whiplash injuries, tennis and golfer's elbow, knee, ankle, shoulder or other joint pain, chronic tendonitis/tendonosis, and musculoskeletal pain related to osteoarthritis. Prolotherapy works by raising growth factor levels or effectiveness to promote tissue repair or growth.<sup>3</sup> It can be used years after the initial pain or problem began, as long as the patient is healthy.

Prolotherapy works by causing a temporary, low grade inflammation at the site

of ligament or tendon weakness (fibro-osseous junction), "tricking" the body into initialing a new healing cascade. Inflammation activates fibroblasts to the area, which synthesize precursors to mature collagen, and thereby reinforcing connective tissue.<sup>3</sup> This inflammatory stimulus raises the level of growth factors to resume or initiate a new connective tissue repair sequence to complete one which had prematurely aborted or never started.<sup>3</sup> Prolotherapy is also known as "regenerative injection therapy (RIT)," "non-surgical tendon, ligament and joint reconstruction," or "growth factor stimulation injection therapy."

### Low Back Pain

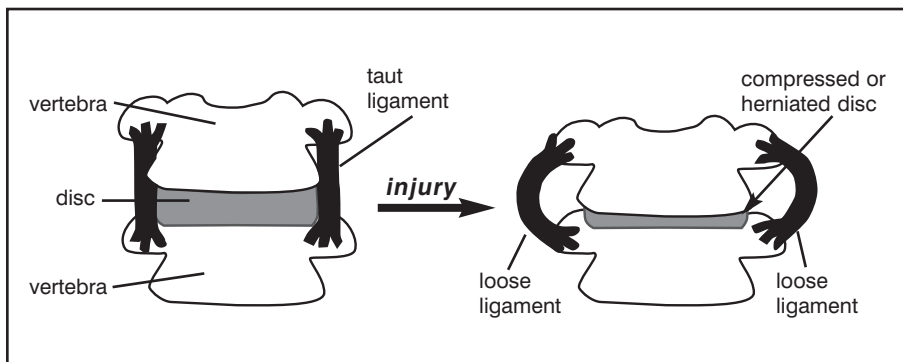
Low back pain is a common medical complaint and, in the United States alone, more than 5 million people are disabled by low back pain, half of these permanently.<sup>4</sup> Low back pain affects most people at some point during their lifetimes. It is the second most frequently reported illness in industrialized countries, next to the common cold.<sup>5</sup> In fact, it has been reported that 80 percent of the general U.S. population will at some time suffer from low back pain, and 20 percent are suffering at

any given time.<sup>6,7</sup> It is the subject of numerous books, articles, and media reports. A variety of sports activities—such as gymnastics, football, weight lifting, rowing, golf, dance, tennis, baseball, basketball, and cycling—have been linked to low back pain.<sup>8</sup> Non-athletes and athletes alike, however, can suffer from this condition.

### Causes of Musculoskeletal Low Back Pain

Ninety percent of low back pain is mechanical. This type of low back pain is the result of overuse or straining, spraining, lifting, or bending that results in ligament sprains, muscle pulls, or disc herniations.<sup>9</sup> Mechanical low back pain is the most common cause of work-related disability in persons under 45 years old.<sup>10</sup> While disc problems have gotten much of the credit for low back pain, ligament injury is a more important source of back pain.<sup>11</sup> In fact, it has been reported that only 4 percent of low back pain is due to a herniated disc.<sup>12</sup>

To understand why the disc has been given so much credit for low back pain, one has to understand some medical history. In 1934 researchers named Mixter and Barr became popular.<sup>13</sup> They focused attention on the disc, giving root to a popular theory and, from that time forward, "disc disease" has overshadowed the ligaments' importance. Then, with the introduction of CAT or CT scanners (Computerized Axial Tomography) in the 1970s, and the popularity of MRIs in the 1980s and 1990s, further attention was focused on the disc as the cause of low back pain—because discs are easily seen in these types of studies. On the other hand, ligament injury often involves very small micro-tears which usually do not show up well on these investigations and so have been largely overlooked.



**FIGURE 1.** As a natural consequence, flattening of a disc due to compression or herniation results in laxity of ligaments attached to the adjacent vertebrae.

### MRIs Are Not a Diagnosis

The Textbook of Orthopedic Medicine (Ombregt et al.) states, “The results of radiographic examinations should never be given to the patient as a diagnosis.”<sup>14</sup> MRIs show disc herniations; however, they do not reveal how old those herniations are or whether that herniation is the cause of the person’s pain. Many studies have documented the fact that abnormal MRI findings exist in large groups of pain-free individuals.<sup>15-21</sup> A study published in the *New England Journal of Medicine* showed that, out of 98 pain-free people, 64% had abnormal back scans.<sup>22</sup> However, many surgeons base their decisions to operate primarily on the outcome of these investigations.<sup>23</sup> It is inevitable, then, that some of the surgeries done are not necessary and will not resolve the pain for which they are intended. Because of this, if the herniation is used as the only basis for a treatment plan, the person’s pain may not improve. And, because MRI’s may also show abnormalities not related to the patient’s current pain complaint, these MRI findings should always be correlated to the individual patient.

During recent years, the idea has become accepted by the general public that a herniated disc requires surgery, especially if the pain has not resolved after a few weeks and there is a positive MRI or CT. However common, this opinion has not been supported by evidence in long-term studies which show, instead, that equally good or better results are obtained after conservative non-surgical treatment. Two studies found no difference between final results of surgical and non-surgical therapy after 7 and 20 years of observation.<sup>24,25</sup> Another study found a 92 percent return-to-work rate in a group treated conservatively, even though 60 percent had muscle weakness and 26 percent showed disc rupture on the CT scan.<sup>26</sup> Therefore, the presence of even large herniations and/or disc ruptures should not be taken as an absolute reason for surgery.<sup>27-29</sup> Due to the risks involved in surgery, conservative treatments—among them Prolotherapy—should always be undertaken first.

### Weak Spinal Ligaments Precede Disc Herniation

Weakening of the spinal ligaments precedes disc herniations.<sup>30</sup> For a disc to herniate, there must first be a primary ligament weakness and a deteriorating disc.<sup>31</sup> Disc degeneration is so common it is considered part of the normal aging process.<sup>32</sup> In the natural course of aging, a disc loses pliability and is less able to withstand normal pressures. Thus, it is more prone to having its outside edges become cracked or torn.<sup>33</sup> If the pressure goes high enough, the fluid in the disc’s center can leak through these cracks or fissures. This also leads to decreased disc height. In addition, the ligament that holds the disc in place becomes lax and weakened. As a result, the joint becomes even more unstable and more likely to herniate (see Figure 1). Ligaments hold the disc in place, so if the ligament weakens, the disc can more easily herniate through it. In fact, increased pressure in the disc, together with increased ligament laxity, is the perfect recipe for disc herniation.<sup>34,35</sup>

### Prolotherapy For Disc Disease

Although initial onset of disc herniations is usually extremely painful and acute, in a few days to a few weeks, the protruding disc segment slowly shrivels away.<sup>36</sup> In fact, with or without treatment, most disc herniations reabsorb and resolve within two to six weeks, with up to 90 percent back-to-normal activity within one month regardless of treatment.<sup>37,38</sup> However, it has been es-

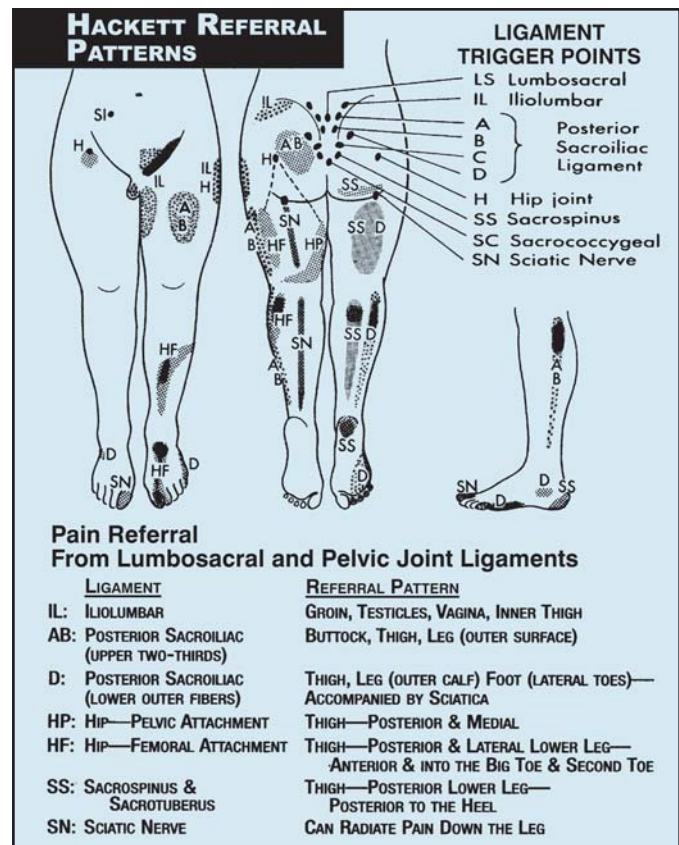


FIGURE 2. Pain referral patterns from lumbosacral and pelvic joint ligaments. From Hauser, “Prolo Your Pain Away,” Second Edition. 2004. Beulah Land Press. Oak Park, IL. Used with permission.

timated that 10 percent of people who suffer a disc herniation continue to have pain and go on to experience chronic back pain that includes muscle pain, spasm, and stiffness (a sign of a ligament laxity and a weak joint), sometimes with pain going down the legs. These symptoms may persist long after the disc herniation itself has shriveled away because of weakened back ligaments and connective tissue support which has not healed. Even after someone has “recovered” from a back injury or disc herniation to the point that he or she is out of severe pain, there still exists a predisposition to further injury at sites where there is ligament weakness. In addition to that, the change in biomechanics when a ligament weakens can contribute towards osteoarthritis in that joint as well as stress on other joints. Prolotherapy can help stabilize and strengthen the ligaments around these weakened joints and reduce or eliminate pain.

### Prolotherapy For Sciatica

Sciatica is defined as “pain emerging from the lower back that is felt along the distribution of the sciatic nerve in the lower extremity.”<sup>39</sup> A diagnosis of sciatica describes a symptom and is not specific in terms of cause. Frequently, the cause of sciatica is attributed to a finding on an MRI such as a disc herniation. However, for the majority of people who experience this type of pain—even in cases when numbness is present—the cause of the problem is not a disc but rather sacroiliac ligament weakness.<sup>40</sup> In fact, it has been stated that ligament laxity in the sacroiliac joint is the number one reason for sciatica and is one of the most common

## CASE REPORTS

### Case #1

A 45-year-old active female housewife with no prior medical or surgical history presents complaining of an 8 month history of low back pain. The patient describes her pain as “24/7” and “like a low voltage electrical pain that never goes away.” She reports no immediate prior trauma to the onset of symptoms, although she had just started skiing as a new sport. Prior to onset of the pain she was a runner and ran 15 miles per week without problem, bicycled, and maintained an active physical lifestyle. The pain started in her back then began to radiate into her left hip, top of her left pelvis, and sometimes into her groin. She was diagnosed with hip flexor syndrome and sent to physical therapy and ultrasound which helped at first, but then began to aggravate and worsen the problem. The pain became so severe that the patient was seen in the emergency department, given morphine, and admitted for a workup. The patient received two epidurals a week apart which did not help, and began taking up to 2400 mg ibuprofen a day along with voltarin. She saw two surgeons who said she was not a surgical candidate. She began having knee pain and received a third epidural which did not help.

**Examination:** Vitals: normal. Lumbar forward flexion mild restriction/extension within normal limits. Straight leg raising negative. Hip internal/external rotation within normal limits bilaterally. Tenderness to palpation at left sacroiliac joint and iliolumbar bilaterally. Neurological and remaining exam normal. MRI shows slight midline protrusion of the disc at L4-5 and very slight encroachment upon the left lateral recess at L5-S1, and with no spinal stenosis. A CT done one month later showed broad based disc bulge at L3-4, L4-5 and L5-S1 without spinal stenosis, as well as degenerative changes on the facets bilaterally, most severe at L4-5 on the right. Bone scan negative.

**Prolotherapy Treatment:** Total of seven prolotherapy treatments, one month apart. Patient noticed 30% improvement after first treatment. After fifth treatment patient reports 90% improvement. Last seen on followup two and a half years later and reports stable at 95% improvement, with return to full activities and no need for any medication.

### Case #2

A 47-year-old male, studio lighting technician, presents complaining of low back pain for many years on and off, with sciatica on and off for the past 2 years. The patient first recalls sciatica after mountain biking 2 years ago. Two weeks ago he was pushing down his right leg on the center stand on his motorcycle and began to have a flare of low back pain and sciatica which was so severe he was not able to walk. He describes it as a “throbbing tooth ache,” level 10/10. He has to take vicodin to sleep and been prescribed Flexeril, ibuprofen and Bextra. He has been trying chiropractic but not much change noted yet. Past medical history revealed appendix out 1987, pericarditis 1990, no other illnesses or surgeries. Review of systems negative except for back pain.

**Exam:** Normal vitals. Gait non-antalgic. Straight leg raising negative, Hip flexion/extension within normal limits bilaterally, tenderness to palpation at bilateral L4-5 facets and upper and lower sacro-iliac ligaments bilaterally, right greater than left. Rest of exam normal with normal neurological exam. MRI shows L3-4 with 8mm lateral disc protrusion along with 4mm central and right disc protrusion. At L4-5, there is diffuse 3mm bulging annulus with midline annular fissure, and bilateral degenerative facet joints. At L5-S1 there is no significant annulus or disc protrusion. No central canal stenosis.

**Prolotherapy Treatment:** Patient received his first prolotherapy treatment 2 weeks after first being seen. He received a total of three prolotherapy treatments, 3 to 4 weeks apart. He was also receiving low force chiropractic treatments concurrently. Patient reports 100% improvement with ability to return to work, lift equipment, and resume normal activities. Followup in 2 months showed stability without return of symptoms and full return to work. In a follow-up call 4 years later, the patient reports still doing well, has had no return of pain or sciatica.

### Case #3

A 31-year-old female with no past medical or surgical history, complaining of low back pain for 14 years since giving a “piggy-back” ride to an adult friend for an hour. The patient had felt “a rubber-band snap” in her back but continued to carry her friend. Prior to this, she had been an active soccer player but gave that up within a few years of this injury. She reports her back pain affects her “every moment,” morning until night. She cannot sit longer than 5 minutes. Her back randomly “goes out” and she can be incapacitated for a period of time. She does not feel pain down her leg except on a couple of occasions over the last few years at which time she felt it down her left leg. Resting helps but it is hard for her to lie flat without her knees bent. She has tried chiropractic with no relief; and massage therapy, and acupuncture, physical therapy, and osteopathic manipulation with only temporary relief.

**Exam:** Normal vitals, gait non-antalgic. Lumbar side bending produces left low back pain. Straight leg raising negative. Hip flexion/extension within normal limits bilaterally. Tenderness at PSIS and iliolumbar as well as bilateral SI. Rest of exam negative. No MRI findings.

**Prolotherapy Treatment:** After 6 treatments at one month intervals, patient noted 80% improvement. She was then seen every 3 to 4 months for 3 additional treatments. She was 95% improved at end of treatment course. Followup call 2 years later finds patient has been doing very well and was able to successfully carry a pregnancy without problem. She reports that carrying her child around has put some stress on her back but that she is still very much improved.

### Case #4

A 67-year-old male business owner complaining of low back and left leg pain on and off over the past 30 years. 4 weeks ago, the pain returned without any specific prior trauma although he had increased his activities. He reports pain start-

ing in his low back and then radiating down the back of the left thigh, with pain also on the front of left leg and radiating down to the ankle. Sitting and walking are difficult. He has tried exercise and chiropractic which has helped a little, and an epidural which did not help but, instead, seemed to aggravate the problem. Past medical history negative except for spinal meningitis in his 20's with full recovery. No major medical problems except elevated blood pressure being treated with blood pressure medication. No surgeries.

**Exam:** Straight leg raising is positive at 70 degrees on the left. Fabere's positive for left SI, with left hip restricted internal/external motion but may be secondary to guarding. Tenderness palpable at bilateral sacro-iliac joints and sacral angles as well as iliolumbar ligaments, left greater than right.

Because of these positive findings on exam, the patient was sent for lumbar spine MRI which showed degenerative discs at multiple levels as well as spinal stenosis at L2-3 and L4-5. 3mm central to left paracentral disc bulging with no stenosis at L5-S1. Hip x-ray normal.

Lumbar spinal stenosis is a relative contraindication for prolotherapy. In most cases, prolotherapy will not resolve pain caused by this condition. However, since this patient's physical exam and history support sacroiliac sprain as either a contributory or overlapping factor, and because the patient did not want surgery, he elected to a trial course of prolotherapy treatment.

**Prolotherapy treatment:** After two prolotherapy treatments the patient reported complete alleviation of all symptoms including leg pain, ability to sleep, sit, walk, and return to full activity, including golf. He was seen 3 months later to ensure stability and reported continuation of 100% improvement and no recurrences. Five years later, he has been stable with no recurrences.

reasons for chronic low back pain.<sup>41</sup>

As discussed in the author's January/February article,<sup>1</sup> ligament referral patterns exist for the low back (see Figure 2). Note that the referral pattern for the sacro-iliac ligaments are similar to those of the sciatic nerve.

Piriformis syndrome is another often overlooked reason for sciatica, leg or buttock pain.<sup>42</sup> The piriformis muscle tendon attaches directly over the exiting sciatic nerve (see Figure 3). Injury, straining, or micro-tears to the piriformis tendon or other surrounding ligamentous structures result in inflammation and swelling and results in pressure on the sciatic nerve.

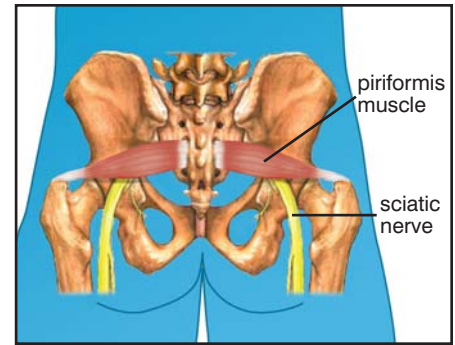
A study by Merriman, evaluating patients treated during his 40 years as a general and industrial surgeon, compared prolotherapy with fusion for sciatic pain. His conclusion was that conservative physiologic treatment by prolotherapy — after a confirmed diagnosis of ligamental and tendinous laxity — was successful in 80 to 90 percent of more than 15,000 patients treated with prolotherapy and had fewer side effects than with fusion.<sup>43</sup>

### Typical Treatment Course

The average number of treatments needed is between 4 and 6, with some people needing more and some people needing less. Prolotherapy can also be successfully used for failed back surgery patients for whom surgery did not resolve their back pain, but these patients may take longer. Typically, some improvement should be noted by the patient after the 2nd or 3rd treatment, with subsequent continued improvement. In some cases, significant improvement is noted after the first treatment. Patients who have been on anti-inflammatories prior to starting treatment may require longer before noticing improvement. If no improvement whatsoever is noted by the patient after 3 to 4 treatments, there should be a re-evaluation for any interfering factors such as poor sleep, diet, continued aggravating activities, illness, or use of medications that may prevent healing. Referral for complementary modalities, radiological studies, or surgical consult should be considered, if indicated.

### Contraindications

Relative contraindications include lumbar central canal stenosis, especially where symptoms and history correlate to an MRI finding. Use of medications that might interfere with healing are also relative con-



**FIGURE 3.** Sciatic nerve as it transverses under piriformis muscle. Injury to the piriformis muscle or surrounding sacroiliac structures can cause swelling and put pressure on the sciatic nerve, causing buttocks and leg pain.

traindications.

Absolute contraindications include neurological signs such as loss of bowel or bladder function, or loss of feeling or movement in the legs. Other absolute contraindications include known, or suspected, cancer, tumor, or medical causes for the pain — such as kidney infection or abdominal aortic aneurism, or any underlying illness that would prevent healing.

### Conclusion

Prolotherapy is a reasonable and conservative approach to musculoskeletal low back pain, disc disease, and sciatica. Since prolotherapy is a treatment modality that provides a long term solution rather than just palliation, it should be considered in appropriate patients prior to long term narcotic therapy or surgical intervention. ■

*Donna Alderman, DO fcis a graduate of Western University of Health Sciences, College of Osteopathic Medicine of the Pacific, in Pomona, California, with undergraduate degree from Cornell University in Ithaca, NY. She has extensive training in Prolotherapy and has been using Prolotherapy in her practice for ten years. Dr. Alderman is the Medical Director of Hemwall Family Medical Centers in California and can be reached through her website [www.prolotherapy.com](http://www.prolotherapy.com).*

### References

1. Alderman D. Prolotherapy for Musculoskeletal Pain. *Pract Pain Mgt.* Jan/Feb 2007. 7(1):10-15.
2. Hackett GS, Hemwall GA, and Montgomery GA. *Ligament and Tendon Relaxation Treated by Prolotherapy, Fifth Edition.* Institute in Basic Life Principles. Oak Brook, IL. 1991.
3. Reeves KD. Prolotherapy: Basic Science, Clinical Studies, and Technique. In Lennard TA (Ed) *Pain Procedures in Clinical Practice, 2nd Ed.* Hanley and Belfus. Philadelphia. 2000. pp 172-190.
4. Frymoyer JW and Cats-Baril WL. An overview of the

- incidences and costs of low back pain. *Orthopedic Clinics of North America*. 1991. 22:263-271.
5. Ibid.
6. Valkenburg HA and Haanen HCN. The epidemiology of low back pain. In White AA and Gordon SL, (eds) *Idiopathic Low Back Pain*. Mosby, St. Louis. 1982.
7. Biering-Sorensen F. A prospective study of low back pain in general population. I. Occurrence, recurrence and aetiology. *Scandinavian Journal of Rehabilitation Medicine*. 1983, 15:71.
8. Drezner J and Herring S. Managing low-back pain. *The Physician and Sportsmedicine*. 2001. 29: 8.
9. Borenstein DG. Chronic low back pain. *Rheumatological Disease Clinics of North America*. 1996. 22:439-456.
10. Hills EC, Wieting JM, et al. (eds). Mechanical low back pain. Updated 21 November 2004. Available at <http://www.emedicine.com/pmr/topic73.htm>.
11. Ombregt L, Bisschop P, and ter Veer HJ. *A System of Orthopaedic Medicine, Second Edition*. Churchill Livingstone. 2003. p 775.
12. Ibid. ref 10.
13. Mixer WJ and Barr JS. Rupture of the intervertebral disc with involvement of the spinal canal. *NEJM*. 1934. 211:210.
14. Ibid. ref 11; Ombregt L, Bisschop P, and ter Veer HJ. p.739.
15. Ibid. ref 11; Ombregt L, Bisschop P, and ter Veer HJ. p.59.
16. MacRae DL. Asymptomatic intervertebral disc protrusion. *Acta Radiologica*. 1956. 46-49.
17. Hitselberger WE and Whitten RM. Abnormal myelograms in asymptomatic patients. *J of Neurosurgery*. 1968. 28:204.
18. Wiesel SW et al. A study of computer-assisted tomography: The incidence of positive CAT scans in an asymptomatic group of patients. *Spine*. 1984. 9:549-551.
19. Powell MC et al. Prevalence of lumbar disc degeneration observed by magnetic resonance in symptomless woman. *Lancet*. 1986. 13:1366-1367.
20. Boden SD et al. Abnormal magnetic resonance scans of the lumbar spine in asymptomatic subjects. *J of Bone and Joint Surgery*. 1990. 72A:503-408.
21. Kaplan PA. MR imaging of the normal shoulder: variants and pitfalls. *Radiology*. 1992. 184:519-524.
22. Deyo R. Magnetic resonance imaging of the lumbar spine-terrific test or tar baby? *NEJM*. 1994. 331:115-116.
23. Ibid. ref 11; Ombregt L, Bisschop P, and ter Veer HJ. p. 700.
24. Hakelius A. Prognosis in sciatica: A clinical follow-up of surgical and nonsurgical treatment. *Acta Orthopaedica Scandinavica*. 1970. 129 (suppl).
25. Nashold BS and Hrubec Z. *Lumbar Disc Disease: A Twenty-year Clinical Follow-up Study*. Mosby, St. Louis. 1971.
26. Alaranta H. A prospective study of patients with sciatica. *Spine*. 1990. 15:1345-1349.
27. Bush K et al. The natural history of sciatica associated with disc pathology. *Spine*. 1992. 17:1205-1222.
28. Delauche-Cavalier MC et al. Lumbar disc herniation; computed tomography scan changes after conservative treatment of nerve root compression. *Spine*. 1992. 17:927-933.
29. Matsubara Y et al. Serial changes on MRI in lumbar disc herniations treated conservatively. *Neuroradiology*. 1995. 37:378-383.
30. Alpers BJ. The problem of sciatica. *Medical Clinics of North America*. 1953. 37:503.
31. Ibid. ref 1; Hackett GS, Hemwall GA, and Montgomery GA. Commenting on work of Newman PH. p 9.
32. Ibid. ref 11; Ombregt L, Bisschop P, and ter Veer HJ. p.729.
33. Acarpglu ER et al. Degeneration and aging affect the tensile behavior of human lumbar annulus fibrosus. *Spine*. 1995. 20:2690-2701.
34. Krag MH et al. Thoracic and lumbar internal disc displacement distribution from in vitro loading of human spinal motion segments: experimental results and theoretical predictions. *Spine*. 1987. 12:1001-1007.
35. Ibid. ref 11; Ombregt L, Bisschop P, and ter Veer HJ. p. 745.
36. Ibid. ref 11; Ombregt L, Bisschop P, and ter Veer HJ. pp 747, 765.
37. Nachemson A. Advances in low back pain. *Clin. Orthop*. 1985. 200:266.
38. Paster RZ. Nonpharmacologic management of low back pain. *Family Practice Recertification Management of Chronic Low Back Pain Special Supplement*. June 1999. 21(7):6.9-21.
39. *Taber's Cyclopedic Medical Dictionary, 19th edition*. F.A. Davis Company. Philadelphia. 1997. p 1851.
40. Hauser R and Hauser M. *Prolo Your Pain Away, 2nd Ed*. Beulah Land Press, Oak Park, IL. 2004. p 90.
41. Schwarzer A. The sacroiliac joint in chronic low back pain. *Spine*. 1995. 20:31-37.
42. Parziale JR, Huddins TH, and Fishman LM. The piriformis syndrome. *American Journal of Orthopedics*. Dec 1996. 25(12):819-23.
43. Merriman J. Prolotherapy versus operative fusion in the treatment of joint instability of the spine and pelvis. *J of Intl Coll of Surgeons*. August 1964. 42(2):150-159.